

Clinical case report on nutritional dystrophy in goats at S. A. Quadary Teaching Veterinary Hospital, CVASU, Chittagong

S. Akter^{1*}, S. Akter¹, M. A. H. M. Kamal², M. N. Islam³, M. A. Hoque¹ and M. M. Rahman¹

¹Department of Medicine and Surgery, Faculty of Veterinary Medicine, Chittagong Veterinary and Animal Sciences University, Khulshi-4225, Chittagong, Bangladesh.

²Customer Service officer, Nourish Poultry and Hatchery Ltd, Fatikchari, Bangladesh.

³Veterinary Consultant, Institute of Epidemiology, Disease Control and Research, Mohakhali, Bangladesh.

Abstract

Background

Nutritional fibrous osteodystrophy may be developed due to dietary deficiency of calcium or dietary excess of phosphorus. Fibrous osteodystrophy (FOD) provokes hyperostotic distortion of cancellous bones, connective tissue proliferation, and poor mineralization of bone. The objectives of this study were to report the clinical characteristics and therapeutic management of FOD in goats.

Materials and methods

Four out of 8 Jamnapari goats developed fibrous osteodystrophy in a small scale intensive household farm in Chittagong. The age range of the affected goats was 4-5 months. The feeding history of goats was primarily wheat bran, gram and pea husk. Blood sample from all affected and non-affected animals and feed sample from household farm were collected for laboratory analysis. Fibrous osteodystrophy was primarily diagnosed by observing clinical signs of mandibular and maxillary enlargement, pain on pressure at the enlarged bone, protruded tongue and dyspnea, which was then confirmed by high level of phosphorus in serum evaluation.

Results

The calcium and phosphorus contents in the sampled gram, pea husk and bran were 0.5%, 0.3% and 0.5%, and 0.71%, 0.49% and 0.61%, respectively. Most of the affected animals had increased serum levels of phosphorus, glucose and alkaline phosphatase and decreased level of calcium. Based on the clinical findings and the laboratory report, the cases were diagnosed as fibrous osteodystrophy due to nutritional imbalance in diet. The owner was advised strictly to stop providing any bran to animals (affected and healthy). Affected animals were additionally treated with calcium preparation, vitamin ADE, ketoprofen, protein, and penicillin-streptomycin combination.

Conclusion

Treatment of fibrous osteodystrophy required a long time recovery along with balanced ration. A combined therapy of calcium and vitamin D and protein preparation is effective for treatment along with adequate green grass and balanced rations.

Keywords: Osteodystrophy, Nutritional imbalance, Calcium, Phosphorus and Goat

*Correspondence: najatdvm@gmail.com

All right reserved 0426/2018

Introduction

Parathyroid glands through producing parathyroid hormone (PTH) are responsible for maintaining calcium homeostasis. Following low circulating ionized calcium levels, PTH causes osteoclastic breakdown of bones, thereby increasing circulating ionized calcium (Fraser, 2009). When low levels of circulating ionized calcium results from disruption of homeostatic mechanisms, vitamin D₃ deficiency and/or chronic kidney failure, secondary hyperparathyroidism can be resulted (Selvi *et al.*, 2009). Fibrous osteodystrophy (FOD) (also called Osteodystrophia fibrosa or Osteitis fibrosa cystica) which provoke hyperostotic distortion of cancellous bones, connective tissue proliferation, and poor mineralization of bone, is one such consequence of secondary hyperparathyroidism (Ospina *et al.*, 2014). Upsurges of persistent Parathormone (PTH) levels in plasma could involve in pathogenesis of FOD and might be associated with primary or secondary hyperparathyroidism (Thompson, 2007). In case of domestic animals primary hyperparathyroidism is rare and may be connected to parathyroid tumors or idiopathic bilateral parathyroid hyperplasia. On the other hand, secondary hyperparathyroidism occurs sporadically and attributed to nutritional imbalance in feed or chronic renal diseases (Bandarra *et al.*, 2011). Insufficiency in dietary calcium or excessive phosphorous diet considered as most common pathological causes of nutritional fibrous osteodystrophy. It mostly affects young animals having diets containing low calcium and relatively high phosphorus contents. The condition resulted from decreased concentration of serum ionized calcium and increased synthesis and secretion of PTH (Radostits *et al.*, 2007). The major clinical features of FOD encompass bone deformities and enlargements, and locomotion or postural disturbs. The disease is more frequently observed in horses (Ospina *et al.*, 2014) and sporadically described in goats, rabbits and other mammals however, lesions tend to be rare in sheep and cattle (Bandarra *et al.*, 2011). All breeds and ages of goats are susceptible after weaning (Smith and Sherman, 2011). Disease predisposition by host factors such as sex are not

reported (Stewart, 2010). The consequences of FOD in affected animal could be nonspecific clinical signs at initial stages and involve progressive lethargy, difficulty in eating and drinking, weight loss, and a preference for recumbency. The mandible is the most susceptible bone shows the detectable anomalies though all bones might be affected gradually. The jaw bone may be palpably soft which restrict the width opening of mouth. Presence of saliva and hanging tongue from mouth also noted. Disruptions of the dental arcades with displacement of individual teeth are common. Teeth may actually point horizontally instead of vertically. Affected animals may have a stiff or painful gait, or be recumbent, due to pathologic fractures that may spontaneously occur in dystrophic bones (Smith and Sherman, 2011). For differential diagnosis the cases are frequently mistaken for lumpy jaw (actinomycosis) which is uncommon in goats. However, FOD is one of the frequently reported clinical problems in goats recorded at Shahedul Alam Quadery Teaching Veterinary Hospital (SAQTVH), Chittagong Veterinary and Animal Sciences University (CVASU). The presenting goats were being reared in intensive household farm. Until now there is no published report of FOD in goats in Bangladesh. Therefore, this study was documented mainly to bring it to the knowledge of practicing veterinarians and veterinary students especially in other parts of Bangladesh.

Materials and Methods

Two affected goats were brought to SAQTVH of CVASU on 28 October, 2014 with varied degrees of maxillary and mandibular swelling accompanied by open mouth, protruded tongue, respiratory difficulty and anorexia. These animals were from a flock of 8 goats of different ages. Another two goats affected with FOD, also found on farm visit on 30 October 2014 presented swollen face (predominantly in the maxilla and in the mandible), partial mouth opening, protruding tongue (Fig.1-2), and mild dyspnea. Blood sample from all affected and non-affected animals and feed sample from household farm were collected for laboratory analysis. The blood samples was drawn by jugular venipuncture using

Clinical case report on nutritional dystrophy in goats

5 ml sterile syringe and transferred to sterile tubes without EDTA before sending to the laboratory of the Department of Physiology, Biochemistry and Pharmacology, CVASU. Blood was allowed to clot and serum was harvested after retraction of clot and stored in -20°C. Fibrous Osteo-dystrophy was primarily diagnosed by observing clinical signs of mandibular and maxillary enlargement, pain on pressure at the enlarged bone, protruded tongue and dyspnea which was then confirmed by elevated level of phosphorus on serum evaluation.

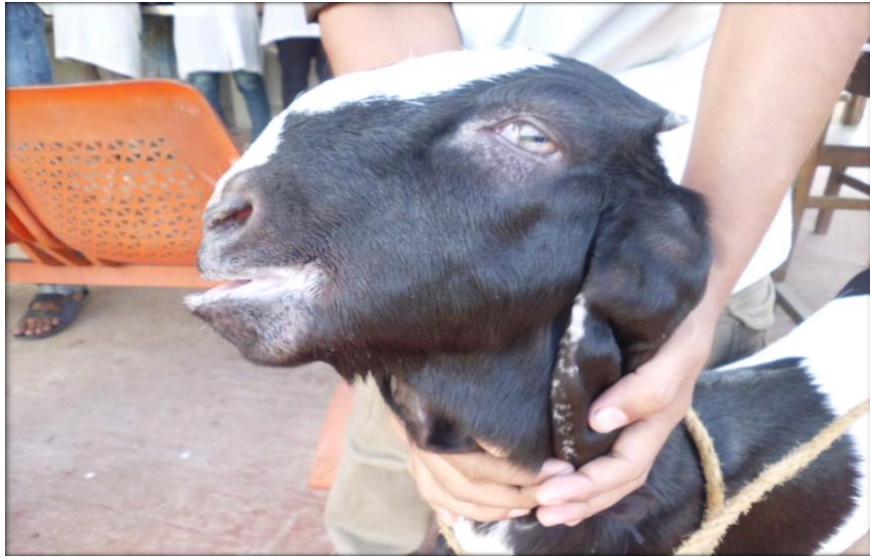

Figure 1. Swollen mandible and maxilla of the FOD affected goat




Figure 2. Protruded tongue of the FOD affected Goat

Procedure of laboratory investigation

Serum samples were analyzed to determine the serum calcium, phosphorus, glucose and alkaline phosphatase by using automatic hematoanalyzer (Model:HumaLyzer 3000,https://www.human.de/products/clinicalchemistry/photometers/humalyzer-3000/). For feed analysis 10 gram of each feed types (wheat bran, gram, pea husk and green roughages) were collected from the farm and analyzed individually to determine calcium and phosphorus level by using biochemical analyzer(Model: Celltacα,https://eu.nihonkohden.com/en/products/invitrodiagnostics/invitrodiagnostics/automatedbloodcellcounters/celltec_alpha-mek6500k.html).

Case Management

The owner was advised to stop any kind of bran feeding immediately to all the animals until the FOD affected ones become fully recovered. Additionally, the affected animals were treated with calcium preparation (Jason calcium®; Jayson Pharmaceuticals Ltd.)@ 5ml intravenously once daily for 7days, vitamin ADE (Renasol AD₃E®; Renata Health Ltd.) @ 2ml intramuscularly once daily every two days interval for five times, amino acid preparation (Aminovit plus vet®; Popular Pharma. Ltd @ 2ml intramuscularly once every alternate day for 2 weeks, ketoprophen (Kynol vet®; Eskayef Pharmaceutical Ltd.) @ 2 ml intramuscularly once daily for five days. Penicillin-Streptomycin combination (Streptopen®; Renata Animal Health Ltd.) @ 1.5 ml intramuscularly once daily for 5 days)was also

prescribed to prevent secondary bacterial gum infection due to loosening of teeth. Hence, the goats were only supplied on concentrate; owners were advised to provide adequate green grass or soft feed like left over vegetables until the goats recovered.

Results and Discussions

Fibrous osteodystrophy in this study was diagnosed by the findings of clinical examination and biochemical and feed analysis. Clinical signs included symmetric hard swellings of the both side of the face in maxilla and mandible, pain on palpation at the swollen region, leg deformities, open mouth and protruding tongue, dyspnea, abnormalities of mastication teeth loosening from socket and difficulty of food intake, bilateral exophthalmos. Abnormal gesture was also recorded during clinical examination. Further exploration revealed that the farm goats were fed with locally available wheat bran, gram and pea husk with minimum amount of green grass. The goats had been kept in an indoor housing system of having only one door with no window. The affected goats were suffering for about 2 weeks and no previous treatment was given. The age range of goat was 4-5 months. Infrequent deworming practices but no vaccination in the flock was reported by the farm owner.

The results of biochemical analysis of serum samples and feed analysis are presented in Table 1 and Table 2, respectively.

Table 1. Results of biochemical analyses of serum of all goats of the affected farm

Goat ID	Serum Calcium (Reference value: 9.0-10.3mg/dl)	Serum Phosphorus (Ref value: 4.2-9.2 mg/dl)	Serum Alkaline phosphatase (Ref value: 93-380 U/L)
1	8.6	8.1	1945
2	9.2	8.6	529.3
3	8.9	4.4	4251
6	7.2	11.2	6850.4
Mean±SD	8.5± 0.88	8.1± 2.80	3393.9± 2768.11
4 (Case)	19.5	14.6	6020.4
5 (Case)	8.6	16.4	878.5
7 (Case)	7.2	8.3	4312.1
8 (Case)	8.5	11.7	4167.5
Mean±SD	10.95± 5.74	12.75 ± 3.54	3844.625 ± 2149.01

Clinical case report on nutritional dystrophy in goats

Table 2. Calcium and phosphorus level in supplied feed of affected goat farm

Feed items	Calcium (%)		Phosphorous (%)	
	Test value	Ref. value	Test value	Ref. value
Gram	0.5	0.26	0.71	0.41
Pea Husk	0.3	0.49	0.49	0.27
Bran	0.5	0.49	0.61	0.82

The low calcium and high phosphorus in serum of affected goats and feed samples of the farm suggest these goats had nutritional imbalance. Dietary insufficiency of calcium and/or excessive dietary phosphorus due to prolonged or monotonous feeding of rations with high phosphorus content is the major causes of developing the pathology called nutritional fibrous osteodystrophy (Ospina *et al.*, 2014). Nutritional hyperparathyroidism usually occurs in young animals having diet with less calcium and relatively more phosphorus contents which is in line with the occurrence of FOD (Aslani, 2001). The affected goats were suffering from mandibular and maxillary enlargements which are characteristic alterations in goats affected by fibrous osteodystrophy. In addition head bones are affected and they become swollen, soft, deformed and predispose to pathological fractures (Bas, 2005). Typical clinical signs and gross lesions of the disease usually develop fast in young animals due to their high rates of bone formation and remodeling which support the present case study (Thompson, 2007). Dyspnea observed in affected goats was associated with enlargement of the maxilla. Apprehension and mastication disorders observed in the affected goats may be attributed to the changes in mandible, maxilla, and teeth. Mandible and maxilla enlargements are characteristic alterations in goats affected by fibrous osteodystrophy (Thompson, 2007). In severely affected goats outward bending of fore limbs and inward bending of hind limbs are sometimes observed (Dr. Md. Mizanur Rahman, 2018, personal communication) and is associated with abnormal gait. It is evidenced that excessive secretion of PTH in case of hyperparathyroidism promote bone resorption and softening of the bones which leads to facial deformity (Toribio, 2011). Whether FOD occurred in the study due to nutritional or renal hyperparathyroidism is not

fully explored, but it was probably due to nutritional reason as supported by the findings of feed analysis (Lynch, 1999). Feed analysis of sample of the diet that all goats was fed revealed average calcium (Ca) and phosphorus (P) contents of 1.3 and 1.81%, respectively (Ca:P ratio, 1.23:1). The Ca concentration analyzed in the feed was less than the recommended Ca requirement (Ca:P=2:1) (Radostits *et al.*, 2007). This suggests these goats had a nutritional imbalance. Lack of green grass also contributes to dependency on concentrate feed. Here all four affected goats in this study showed high phosphorus, alkaline phosphatase and low calcium serum levels. High activity of alkaline phosphatase is a characteristic laboratory finding of the condition in goats due to bone pathology (Varshney *et al.*, 2018). As in other species, serum AP is higher in young animals compared with adults due to AP activity associated with the increased osteoblast function of growing bone (Smith and Sherman, 2011). In this study a very high level of AP was detected both in the affected as well as apparently healthy goats. The actual cause of this variation is unknown but it might be due to individual variations and that is why in the apparently healthy animals the clinical signs were not visible. To the best of our knowledge, there is no specific species or breed susceptibility reported so far for osteodystrophy. Any stall-fed goats reared mainly on cereal rich concentrate mixture can develop fibrous osteodystrophy. Osteodystrophy is also reported in other species including horses, rabbit, camel, antelopes (Radostits *et al.*, 2008; Bas *et al.*, 2005; Grandi *et al.*, 2011). The current cases are reported from single Jamunapri goat farms, which supplied mainly with concentrate. However, other goat breeds e.g Black Bengal goats admitted at SAQTVH are found to be affected with FOD for treatment purposes. Therapeutic management of FOD case is variable. If the condition is

Akter and others

diagnosed early, reversal of clinical lesions is possible by dietary management involving reduction of phosphorus levels and correction of the calcium phosphorus ratio (Riet-Correa, 2004). This study showed that Ca and Vit. ADE combinations can be used to correct clinical condition of the affected goats. Vit. D helps in Ca absorption from the intestines (Radostits *et al.*, 2007). Protein supplement provides additional nutritional support and it has been found that these affected goats are supposed to suffer from hypoproteinemia from anorexia and difficulty in swallowing. Loosening of teeth is seen in affected animal. As a result there is possibility to infection due to feed trapped in gums. Hence, combined broad-spectrum antibiotic can be useful to prevent gum infection. Therefore, the antibiotic was used in the treatment of the FOD in the case study. However, success of the treatment was related to severity of clinical signs (Ozmen, 2017). Sometimes the recovery period extends up to 4-5 months provided proper care should be taken. Although it is a well-known disorder, this paper includes a well-documented case of caprine FOD in Bangladesh context.

Conclusions

High phosphorus and low calcium containing concentrates are attributed to FOD. Adequate green grasses are therefore recommended for the goat reared in intensive farming system. Providing balanced nutrition along with supportive treatment could be helpful to manage FOD.

Funding

The study was funded by SAQTVH of Chittagong Veterinary and Animal Sciences University. There is no role of the funding body in designing the study and collection, analysis, and interpretation of data and in writing the manuscript.

Competing Interest

The authors declare that they have no competing interests.

Acknowledgement

The authors would like to thank the animal owner, the staffs of the Department of Medicine and Surgery and Department of Physiology,

Biochemistry & Pharmacology, CVASU, Bangladesh for their cordial supports during the work.

References

1. Aslani MR, Movassaghi AR, Mohri M, Seifi HA. Outbreak of osteodystrophia fibrosa in young goats. *Journal of Veterinary Medicine Series A*. 2001;48(7):385-9.
2. Bandarra PM, Pavarini SP, Santos AS, Antoniassi NA, Cruz CE, Driemeier D. Nutritional fibrous osteodystrophy in goats. *Pesquisa Veterinária Brasileira*. 2011;31(10):875-8.
3. Bas S, Bas A, López I, Estepa JC, Rodríguez M, Aguilera-Tejero E. Nutritional secondary hyperparathyroidism in rabbits. *Domestic Animal Endocrinology*. 2005;28(4):380-90.
4. Fraser WD. Hyperparathyroidism. *The Lancet*. 2009;374(9684):145-58.
5. Lynch MJ, Slocombe RF, Harrigan KE, Laing CJ. Fibrous osteodystrophy in dromedary camels (*Camelus dromedarius*). *Journal of Zoo and Wildlife Medicine*. 1999; 1:577-83.
6. Marais JP. Factors affecting the nutritive value of kikuyu grass (*Pennisetum clandestinum*)-a review. *Tropical Grasslands*. 2001;35(2):65-84.
7. Ospina JC, Doncel B, García NV. Maxillofacial fibrous osteodystrophy in equine: case report. *Brazilian Journal of Veterinary Pathology*. 2014;7(2):100-5.
8. Özmen Ö, Şahinduran S, Aydoğan YA, Sevgisunar NS, Haligur M. Clinical and pathological studies on nutritional fibrous osteodystrophy in goats. *Ankara Üniversitesi Veteriner Fakültesi Dergisi*. 2017;64(1):55-9.
9. Otto M, Radostits C, Kenneth W, Constable P. *Veterinary Medicine: A textbook of the diseases of cattle, horses, sheep, pigs and goats*. 10th edn. London: Saunders Co. Ltd.;2006.
10. Riet-Correa F. Mineral supplementation in small ruminants in the semiarid region of

Clinical case report on nutritional dystrophy in goats

- Brazil. *Ciência Veterinária nos Trópicos*. 2004;7(2/3):112-30.
11. Selvi F, Cakarer S, Tanakol R, Guler SD, Keskin C. Brown tumour of the maxilla and mandible: a rare complication of tertiary hyperparathyroidism. *Dent maxillofacial Radiology*. 2009;38(1):53-58.
 12. Smith MC, Sherman DM. *Goat medicine*. 2nd ed. John Wiley & Sons. 2011; p. 88
 13. Smith MC, Sherman DM. *Goat medicine*. 2nd ed. John Wiley & Sons. 2011; p. 137
 14. Stewart J, Liyou O, Wilson G. Bighead in horses—not an ancient disease. *Australian Equine Veterinarian* . 2010;29:55-62.
 15. Thompson K. *Bones and Joints*. Jubb, Kennedy, and Palmer's *Pathology of Domestic Animals*. 5th ed. Ontario: Saunders Elsevier. 2007; p.82-88.
 16. Weisbrode SW. *Bone and joints. Pathologic Basis of Veterinary Disease*. 4th ed. Mosby, St Louis. 2007; p.1075-1076.