

### **CASE REPORT**

#### **Surgical management of metatarsal fracture using wire suture in a sheep: A case report**

M. A. Akter, M. R. Alam, M. M. Alam\*

Department of Surgery and Obstetrics, Bangladesh Agricultural University, Mymensingh-2202

M. A. Akter ([antora41292@bau.edu.bd](mailto:antora41292@bau.edu.bd)); M.R. Alam ([alammr@bau.edu.bd](mailto:alammr@bau.edu.bd)); M. M. Alam ([mahmud.dso@bau.edu.bd](mailto:mahmud.dso@bau.edu.bd))

#### **Abstract**

**Background:** The most frequent orthopedic condition that prevents animals from moving normally is a long-bone fracture. The diagnosis and surgical treatment of closed metatarsal fracture in sheep are the main goals of this study.

**Materials and Methods:** A three-month-old female sheep was presented with a history of the left metatarsal bone losing its function, pain at the fracture site, aberrant motion in the affected leg, and fluid or exudate flowing from the fracture site. While radiographs indicated an oblique metatarsal fracture of the left hind limb, palpation of the left metatarsal bone revealed discomfort and fracture fragments. Following internal stabilization with cerclage wire suture, the fracture was treated. Surgery was carried out following the proper immobilization, aseptic procedure, and anesthetic protocol (atropine 0.04 mg/kg BW intramuscularly, five minutes later: xylazine 0.06 mg/kg BW intravenously).

**Results:** The sheep was released from the hospital after the procedure bearing weight on the limb effectively and without any issues. A successful clinical outcome was obtained after surgical alteration.

**Conclusions:** Open fractures necessitate swift, aggressive debridement, stability of the fracture, and early soft tissue restoration. The only practical method for managing fractures may be early surgical treatment and post-operative care.

**Keywords:** fracture, surgical treatment, calves, cerclage wire

\*Correspondence: [mahmud.dso@bau.edu.bd](mailto:mahmud.dso@bau.edu.bd)

All right reserved 0469/2022

## **Introduction**

A fracture is a breach in the continuity of a bone that can be brought on by trauma or twisting as a result of a muscle spasm. On the other hand, a traumatic fracture is brought on by a fall, accident, or other external force (Pravakar *et al.*, 2012). One of the most frequent orthopedic conditions affecting young ruminants is a long bone fracture. The most often fractured bones in sheep and goats are the metatarsus, metacarpus, radius, ulna, and femur (Kofler *et al.*, 2017). Due to the thick covering muscle, the majority of femur fractures are seen to be closed fractures (Beale, 2004). In order to improve the speed and effectiveness of the damaged area's return to function, the goal of fracture repair is to create precise alignment and rigid fixation of the bone. Numerous advancements have been made in the internal fracture fixation of small animals, including better fixation methods and a wider range of implants (Tercanlioglu and Sarierler, 2009). Long bone fractures typically cannot be treated conservatively; instead, some type of internal fixation is usually necessary (Beale, 2004). Proper surgical management, preservation of soft tissues and their connections to bone fragments, anatomic or indirect reduction, adequate stabilization, provision of appropriate and usage of an implant system, and proper postoperative care are all important considerations in fracture repair (Bishnoi *et al.*, 2013; Stiffler, 2004). The objective of this report is to discuss the clinical and radiographic examination of metatarsal fracture in a sheep as well as the successful reduction of the fracture using a suture wire.

## **Materials and methods**

### **Case history**

A three-month-old female sheep weighing 12 kg with a history of a closed fracture in the left metatarsal bone was admitted to Bangladesh Agricultural University Veterinary Teaching Hospital (BAUVTH), Mymensingh. After being run over by a car, the owner of the patient

reported that the sheep had lost function of the left metatarsal bone, pain at the fracture site, and abnormal mobility of the affected leg.

### **Clinical assessment**

After clinical examination, the fracture site on the left hind limb was found to be painful and crepitant. Metatarsal bone pieces with an oblique fracture were felt when the area was palpated and also radiography showed an oblique metatarsal fracture of the left hind limb (Figure 1). Temperature, heart rate, and respiration rate were within the normal range.

### **Treatment**

Surgery is the preferred method for treating this kind of fracture when it comes to fracture treatment. By supporting fragmented bone, several internal fixation devices have been employed to treat near and open fractures. In lengthy bone fractures, wire suture, intramedullary pinning, and/or combinations of these are the most often employed internal fixing methods. In this study, a wire suture was utilized to treat oblique metatarsal bone fractures.

### **Patient preparation and anesthetic protocol**

Povidone-iodine (Povin®, Opsonin Pharmaceuticals Ltd., Bangladesh) and 70% alcohol were used to surgically prepare the shattered limb. The shattered limb was placed down, and the other limb was held out of the way as the sheep was lying on its side. To cordon off the non-sterile portions, the distal end of the limb was wrapped with sterile gauze. The limb was sufficiently wrapped to reveal the broken portion of the bone.

Atropine sulphate (Atrovet®, Techno Drugs Limited, Narsingdi, Bangladesh) was administered intramuscularly to the sheep as a premedication at a dose of 0.04 mg/kg body weight. Xylazine hydrochloride (Xyla®, Interchemie Werken, Holland) was administered intravenously at a dosage of 0.06 mg/kg body weight five minutes later to induce sedation. Intravenous regional anesthesia and infiltration

### *Fracture repair by wire suture in sheep*

analgesia was performed with 2% Lidocaine Hydrochloride (Lidocaine Plus<sup>®</sup>, Techno Drugs Ltd., Narsingdi, Bangladesh). Through jugular venipuncture, intravenous fluid therapy with regular saline solution (Saloride<sup>®</sup>, Beximco Pharmaceuticals Ltd., Tongi, Bangladesh) was started prior to surgery, maintained during surgery, and continued up until anesthesia recovery.

#### **Surgical manipulation**

A skin incision was done directly over the fracture site after aseptically prepping the surgical site (Figure 2a) and holding the sheep in the proper position on the table. The damaged bone was subsequently exposed by forcefully dissecting the subcutaneous tissues (Figure 2b). Thus, the fracture location was visible. Exudates, necrotic muscles, blood clots, and tissue fragments were eliminated. It took a lot of ordinary saline (0.9% NaCl) to properly clean and cleanse the wound. Polyglantin 910 (VICRYL<sup>®</sup>, Johnson and Johnson Privet Limited, India) was used to ligate significant arteries and veins. Bone holding forceps were used to hold the exteriorized fracture pieces while aligning them as closely as feasible to their natural anatomical positions. Then, using stainless steel 0.05-gauge wire, broken fragments were spaced 2 cm apart (Figure 2c) and stitched together using a complete cerclage suture pattern. The wire was wrapped around the bone with similar amounts of strain on both sides to create a full cerclage suture (Figure 2d). In order to prevent the wire from slipping, the wire suture was first inserted into the bone using a bone drill. Vicryl in size 1-0 (VICRYL<sup>®</sup>) was used to suture muscle and fascia (Figure 2e). Simple interrupted nylon sutures were used routinely to seal the skin (Figure 2f). After sealing the skin in the bottom part, an artificial drainage canal was established to allow the serous fluid drain out. Iodine was rubbed over

the suture line, and after rolling the broken area in gauze, splints (made of bamboo sticks and coated in cotton) were put around it.

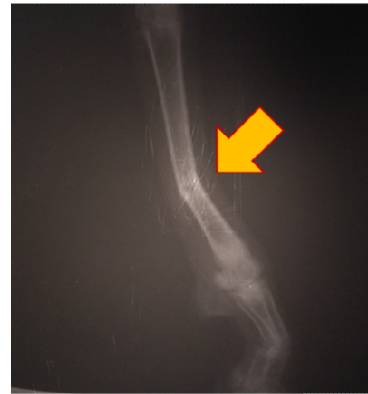

Figure 1. Preoperative radiograph in sheep showing oblique metatarsal fracture of the left hind limb

#### **Postoperative follow up**

The antibiotic ceftriaxone 30 mg/kg BW was administered as part of the surgical procedure for seven days. The owner was also advised to administer ketoprofen 1 mg/kg BW for three days, chlorpheniramine maleate 1 mg/kg BW for five days, and clean the surgery site aseptically every other day. Satisfactory alignment and healing progress was seen when the radiographs were examined on day 28 post-operation (Figure 3). At four weeks, the sheep was utilizing the leg to support its entire weight and had barely any clinical signs of lameness. Additionally, we discovered that there were no problems like edema, hematoma, fluid buildup, inflammation, or wound dehiscence at the wire suture site in the surgical wounds.

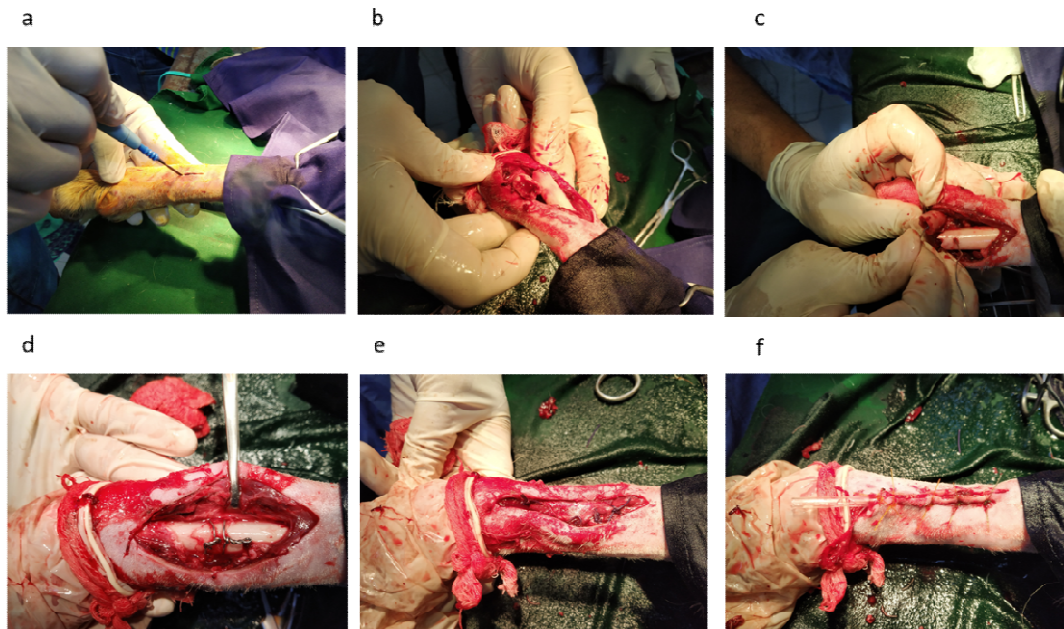


Figure 2. Cerclage suture using stainless steel wire. a) giving skin incision, b) exteriorizing fractured bone, c) introducing wire within bone fragments, d) uniting the two ends of wire, e) muscle suture, f) skin suture and establishment of draining system with a saline catheter.

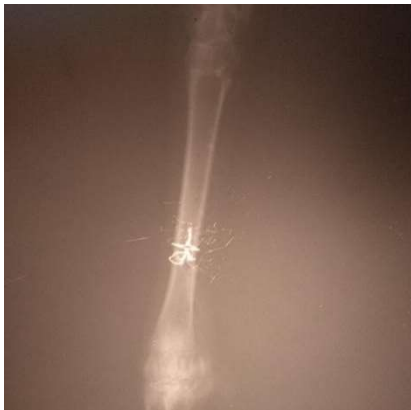

Figure 3. Radiographs showing satisfactory alignment and healing progress on day 30 post-operation.

### Discussion

We described the successful surgical treatment of a closed metatarsal fracture in a sheep with

cerclage wire suture. The most frequently broken bone in ruminants is the metatarsal (Beale, 2004), contrary to Kushwaha *et al.* (2011). The left leg fractures somewhat more frequently than the right (Prabhakar *et al.*, 2012). Metatarsal fractures in calves are most frequently brought on by severe traction during birth, car accidents, unintentional falling or jumping, and abuse or beating (Ali, 2013). Comparing the various fracture types, calves had a higher prevalence of transverse fractures (55%, n=53) than other types of fractures (Simon *et al.*, 2010). On the other hand, oblique fractures were observed to occur more frequently than other forms of fractures (Kushwaha *et al.*, 2011; Jani *et al.*, 2014). Oblique and transverse fractures are more common, which suggests that bending or compression forces were the main forces acting on the long bones (Bishnoi *et al.*, 2013). Long bone oblique fractures were used for this study's suture wire. Metatarsal fractures are frequently seen in young animals under a year old (Beale,

## Fracture repair by wire suture in sheep

2004). This is due to the fact that juvenile animals are very lively and develop coping mechanisms for environmental hazards through experience. Their bones are also weaker than those of the elderly. In young animals, skeletal maturity is attained between 5 and 18 months (Patel *et al.*, 2012).

In the earlier, anatomically reduced fractures were securely stabilized using pins, wires, screws, and plates as internal fracture fixation techniques (Stiffler, 2004). Orthopedic pins are typically utilized in conjunction with wires, bone plating, or external skeletal fixation as a major means of stabilization for internal fixation (Tercanlioglu and Sarierler, 2009). By encouraging axial micromotion and shielding fracture patients from disuse atrophy and muscle contractures, early ambulation speeds up fracture healing (Radke *et al.*, 2006). This study demonstrated full union of the fracture, early ambulation of fracture care, and patient use of the limb.

### Conclusion

Cerclage wires provided the fracture with exact alignment and firm fixation. This made it possible to walk sooner after surgery and speed up the healing process for the bones. It's critical to use a post-operative broad-spectrum antibiotic to fight any infection that could cause osteomyelitis and complicate recovery.

### Acknowledgment

We thank the Director of BAUVTH, ymensingh for allowing us to perform the surgery.

### Conflict of Interest

The authors have no conflict of interest.

### Reference

1. Ali LMB. Incidence, occurrence, classification and outcome of small animal fractures: A retrospective study (2005 - 2010). *International Journal of Biological, Biomolecular, Agricultural, Food and Biotechnological Engineering*. 2013; 7(3): 191-196.
2. Beale B. Orthopedic clinical techniques femur fracture repair. *Clinical Technique of Small Animal Practice*. 2004;19(3): 134-150.
3. Bishnoi AK, Raghunath M and Saini NS. Classification and characterization of comminuted long bone fractures in dogs. *Veterinary Practitioner*. 2013; 14 (1):186-189.
4. Jani SMY, Kushwaha RB, Gupta AK, Malik K and Soodan JS. Occurrence of fractures in dogs: A retrospective study of five years. *Indian Journal of Veterinary Surgery*. 2014; 35(1): 73-74.
5. Kofler J, Hochschwarzer D, Schieder K, Osova A and Vidoni B. Limb fractures in 32 small ruminants – treatment and outcome. *Tierärztliche Praxis Ausgabe G: Grosstiere – Nutztiere*. 2017; 45: 201-212.
6. Kushwaha RB, Gupta AK, Bhadwa MS, Sharad LK and Tripathi AK. Incidence of fractures and their management in animals: a clinical study of 77 cases. *Indian Journal of Veterinary Surgery*. 2011; 32(1): 54-56.
7. Patel TP, Mistry JN, Patel PB, Panchal KN and Gami MS. Clinical and radiographic evaluation of tibia fracture management using intramedullary pinning - a study in three calves. *IntasPolivet*. 2012; 13: 435–439.
8. Prabhakar V, Raghunath M, Singh SS, Mohindroo J, Singh T and Verma P. Clinical management of metacarpal and metatarsal fractures in two buffalo-calves. *IntasPolivet*. 2012; 13: 395–398.
9. Radke H, Aron DN and Applewhite A. Biomechanical analysis of unilateral external skeletal fixators combined with IM-pin and without IM-pin using finite-element method. *Veterinary Surgery*. 2006; 35: 15-23.
10. Simon MS, Ganesh R, Ayyappan S and Kumar RS. Incidence of pectoral limb fractures in dogs: A survey of 331 cases. *Tamilnadu Journal of Veterinary and Animal Sciences* 2011; 7(2): 94-96.

*Akter and others*

11. Stiffler KS. Internal fracture fixation. *Clinical Techniques in Small Animal Practice*. 2004; 19(3): 105-113.
12. Tercanlioglu H and Sarierler M. Femur fractures and treatment options in dogs which brought our clinics. *Lucrări Stiintifice MedicinăVeterinară*. 2009; 13 (2): 98-101.